Radiographic, Surgeon and Owner Assessment of the BioMedtrix TATE® Elbow Arthroplasty

Ricardo J. R. De Sousa[1], Kevin J. Parsons[4], Martin R. Owen[2], James Grierson[1], W. Malcolm McKee[3], Elvin Kulendra[5], and Neil J. Burton[4]

[1]Anderson Moores Veterinary Specialists, The Granary, Bunstead Barns, Pole Lane, Hursley, Winchester, Hampshire, UK, [2]Dick White Referrals, Newmarket, Six Mile Bottom, Suffolk, UK, [3]Willows Referral Service, Solihull, West Midlands, UK, [4]Langford Veterinary Services, University of Bristol, Langford House, Langford, Bristol, UK, and [5]The Royal Veterinary College, Small Animal and Surgery, North Mymms, Hatfield, UK

Corresponding Author
Neil Burton
Langford Veterinary Services
Langford House
Langford
Bristol BS40 5DU, UK
neil.burton@bristol.ac.uk

Submitted June 2015
Accepted May 2016

DOI:10.1111/vsu.12508

Objective: To report the long-term radiographic and clinical outcome of the BioMedtrix TATE elbow arthroplasty system in dogs. Assessment was via radiographs, a surgeon-based questionnaire, and owner assessment of outcome using the Liverpool osteoarthritis in dogs (LOAD) and canine brief pain inventory (CBPI) questionnaires.
Study design: Retrospective multicenter, case series.
Animals: Client-owned dogs undergoing TATE elbow arthroplasty.
Methods: Questionnaires were distributed to surgeons in the United Kingdom performing TATE elbow arthroplasty and to the owners of the dogs operated on. Owners completed the LOAD and CBPI questionnaires. All completed questionnaires from surgeons and owners, and radiographs of the dogs were collated and analyzed.
Results: Surgeon questionnaires and radiographs were obtained for 33 elbows from 32 dogs, with owner questionnaires obtained for 19 dogs. Perioperative, short-term, and mid-term complication rates were 60%, 15%, and 15%, respectively. Radiographic assessment of component alignment showed 62% of cartridges were valgus or varus malaligned and 56% of cartridges were either translated medially or laterally relative to the long axis of the ulnar. There was no significant association between component alignment and final clinical outcome. Surgeon assessment reported 24% of dogs to have full, 52% acceptable, and 24% unacceptable outcome. Owner assessment showed significant decreases in pain severity and pain interference from preoperative to final status but no change in mobility scores.
Conclusions: A high complication rate and variability in component placement was recorded with TATE athroplasty. However, component malalignment did not negatively impact clinical outcome. Final clinical outcome was favorable for most cases with significant reductions in pain severity and interference scores despite no changes in mobility scores.

Elbow dysplasia has a high prevalence in breeds such as the Labrador Retriever, with an estimated UK prevalence of 17%.[1] Lameness associated with the articular and subchondral changes of elbow dysplasia have prompted many surgical treatments aimed at ameliorating pain and slowing progression of osteoarthritis (OA).[2–7] However, OA is often present at the time of diagnosis and progression of OA is inevitable.[8] Pain and lameness unresponsive to conservative management may be indication for salvage procedures such as joint arthroplasty, arthrodesis, or amputation.

Canine elbow arthroplasty was initially described in research dogs.[9] Constrained,[9] cemented,[10,11] hybrid,[12] and cementless[13–15] semi-constrained systems have been described. The BioMedtrix TATE® arthroplasty system (BioMedtrix, Boonton, NJ, USA) is a bicomponent cementless resurfacing prosthesis implanted as a single cartridge with a set plate, after a drill and mill preparation of the joint centered on the humeral trochlea. First generation and second generation versions of this arthroplasty system are commercially available (Fig 1). A third generation tricomponent system, resurfacing the radius, ulna, and humerus each with separate components, is currently in development (personal communication, Sidebotham C, October 2014).

The majority of elbow arthroplasty systems have not been critically reviewed for the ability to accurately replicate the center of joint rotation, clinical efficacy, longevity, or short- and long-term complications. Longitudinal studies in dogs would be important for review and refinement of implant design, technique and patient selection.[16] Use of gait analysis,[17] activity monitoring,[18] or owner questionnaire[19–22] offers methods for postoperative assessment. Use of a validated, owner questionnaire such as the Liverpool osteoarthritis in dogs (LOAD) questionnaire,[22] is a cost-effective and accessible method to measure pain and function in dogs with

Veterinary Surgery 45 (2016) 726–735

OA. The LOAD has shown positive correlation with force plate analysis and the canine brief pain inventory (CBPI)[23] and has been used as part of a multicenter study quantifying owner perception of outcome in dogs undergoing total hip replacement.[24]

The aims of this study were to conduct a retrospective multicenter radiographic, surgeon and owner (LOAD and CBPI questionnaire) assessment of long-term outcome after implantation of first generation BioMedtrix and second generation TATE elbow arthroplasty systems.

MATERIAL AND METHODS

Questionnaires

A surgeon questionnaire (Supporting Information, Supplement 1) was sent to surgery specialists in the United Kingdom who had attended a BioMedtrix TATE arthroplasty course, had completed the certification program, and were performing TATE arthroplasty. They were invited to complete the questionnaire for each dog (each elbow) that underwent elbow arthroplasty. Surgeons were asked to obtain verbal consent from owners for inclusion of the dogs' clinical data. The questionnaire comprised 4 sections: 1) Contact information and signalment, 2) Preoperative assessment (date, general and orthopedic history, exercise regimen, lameness score [Likert scale of 0–10],[25] goniometric measurement of range of motion,[26] forelimb function and medication), 3) Surgery (first or second generation implant, size of implant, anesthesia and surgery duration, antibiotic protocol, complications, hospitalization duration, range of motion, forelimb function, medication, postoperative exercise regimen), and 4) Postoperative follow-up (orthopedic and radiographic assessment, short- and long-term complications, and surgeon satisfaction).

Each owner was sent a questionnaire (Supporting Information, Supplement 2), comprising LOAD, CBPI, and questions specific to the surgery. The questionnaire comprised 3 sections: 1) Preoperative, 2) Operative (at the time of surgery), and 3) Final status (time of questionnaire completion). An aggregate mobility score, and average pain severity and pain interference scores were generated for each dog. Completed questionnaires were assessed by two authors (RDS/NB).

Radiological Analysis

Surgeons were asked to submit all radiographs for each dog (elbow) undergoing elbow arthroplasty. Radiographic reexamination was performed by 2 independent observers (RDS/NB) on 2 occasions, 2 weeks apart. Radiographic presence of preoperative osteophytosis was assessed using previously defined criteria by the International Elbow Working Group (IEWG).[27] The position and orientation of the TATE components were objectively identified on immediate postoperative radiographs (see below) by measurements calibrated relative to a radiographic marker on each image. For elbows where infection was not reported, humeral and radioulnar component-bone interface (CBI) on the mediolateral radiograph was graded and compared between immediate postoperative radiographs and final radiographs. Templates were constructed using the original DICOM files and computer software (OsiriX MD Pixmeo, Bernex, Geneva, Switzerland) for repeatable assessment of component position and CBI.



Figure 1 Evolution of the TATE arthroplasty components. (A) First generation cartridge with a cobalt-chrome (CoCr) humeral component and ultra high molecular weight polyethylene (UHMWPE) radioulnar component with CoCr backplate. Components were backed with sintered beads and solid posts. (B) Second generation cartridge with titanium alloy components and UHMWPE bearing attached to the radioulnar component. (C) Modified profile of the radioulnar component (red shaded region removed) to reduce articular constraint and force transmitted though the implant-bone interface. Components are backed with titanium plasma and hydroxyapatite and posts are hollow and segmented. (D) Third generation cartridge (in development) is a tricomponent system resurfacing the humerus, radius and ulna with individual components (Images reproduced courtesy of BioMedtrix).

Mediolateral Radiograph (Fig 2A). A circle of best fit was superimposed over the articular margin of the humeral component (green). In a variant from the previously described technique for defining the central axis of the humerus,[28] 2 circles were then drawn within the distal humeral shaft (orange) to define a central axis of the bone. Two lines were then drawn (yellow) bisecting these 2 circles and delineating the proximal edge of the humeral component. The angle between these 2 lines defined the angle of insertion of the humeral component relative to the humeral long axis and was defined as the humeral component angle. A line was then drawn (blue) from the center of the circle outlining the articular margin of the humeral component to the apex of the epicondylar osteotomy. This distance was defined as the epicondylar osteotomy apex height.

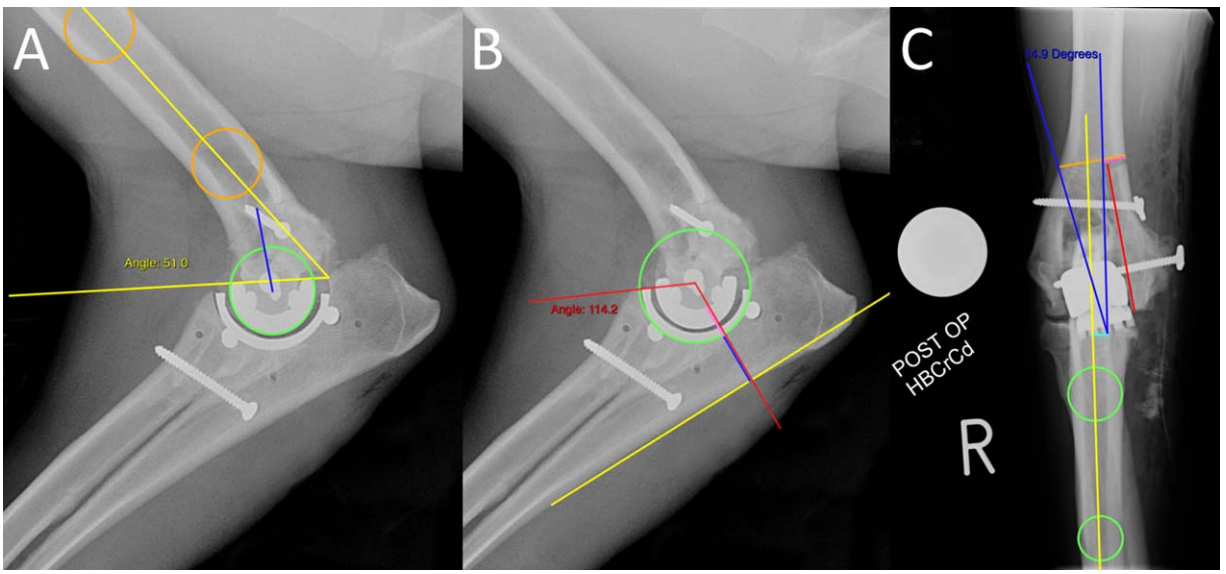

Figure 2 TATE component position measurements. (A) Mediolateral view for humeral measurements. (B) Mediolateral view for radioulnar component measurement. (C) Craniocaudal view for component alignment measurement.

For radioulnar component measurements (Fig 2B), a circle of best fit was superimposed over the osseous margin of the radioulnar component (green). A line was then drawn defining the caudal aspect of the ulna (yellow). Two lines (red), one bisecting the line along the caudal aspect of the ulna at the narrowest isthmus width of ulna and the other aligned with the cranial margin of the radioulnar component were drawn. The angle between these 2 lines defined the angle of insertion of the radioulnar component relative to the ulnar transverse axis and was defined as the radioulnar component angle (RUCA). In addition, the ulnar isthmus distance (blue line) as well as the width of the TATE cartridge along this line (pink) allowed calculation of the ratio of cartridge: ulnar isthmus.

Measurement of CBI was performed by the dividing the humeral and radioulnar CBIs into 3 zones each (total 6 zones, Fig 3) The CBI in each zone was graded 0 through 5; Grade 0—no gap between component and bone; Grade 1—no gap between component and bone but focal lucency present; Grade 2—gap <1 mm between component and bone; Grade 3—gap 1–2 mm between component and bone; Grade 4—gap 2–3 mm between component and bone; Grade 5—gap >3 mm between component and bone (Fig 4).

Craniocaudal radiograph. Two circles (green) were drawn within the ulnar shaft defining the central axis of the bone (Fig 2C). A line (yellow) was then drawn bisecting these 2 circles defining the long axis of the ulna. Two lines were then drawn (blue), the first bisecting the distal and proximal extent of the cartridge and the other parallel with the yellow line. The angle formed between the blue lines was either defined as positive if the medial aspect of the cartridge was more proximal than the lateral aspect (ie, components were in varus relative to the ulnar long axis) or negative if the medial aspect of the cartridge was more distal than the lateral aspect (ie, components were in valgus relative to the ulnar long axis). Cartridge angulation was categorized for statistical analysis as varus malalignment (angle $>+5°$), neutral alignment (angle $-5°$ to $+5°$) or valgus malalignment (angle $<-5°$). Ulnar component recession defined translation of the cartridge from the ulnar midline (cyan). Medial translation was defined positive ($>+2$ mm) and lateral translation defined negative (<-2 mm). Cartridge translation between -2 and $+2$ mm was defined as closely inserted relative to the ulnar long axis. The height of the epicondylar osteotomy referenced from the articular surface of the humerus (red), the epicondylar osteotomy depth (EOD, pink) and the humeral metaphyseal width (HMW, orange) at the level of the epicondylar osteotomy were recorded.

Complications

Complications were noted according to clinical impact as previously defined.[29] Briefly, minor complications required no additional medical or surgical treatment. (eg, wound inflammation, seroma formation). Major complications required medical treatment (eg, infection) or further surgery (eg, fracture, implant failure) for resolution. Catastrophic complications caused permanent unacceptable function. Complications was categorized as perioperative (pre, intra, and postoperative 0–3 months), short-term (3–6 months postoperative), mid-term (6–12 months postoperative), and long-term (>12 months).[29]

Followup and Outcome

Physical examination of all dogs was performed by the attending surgeon at 6–8 weeks postoperative and

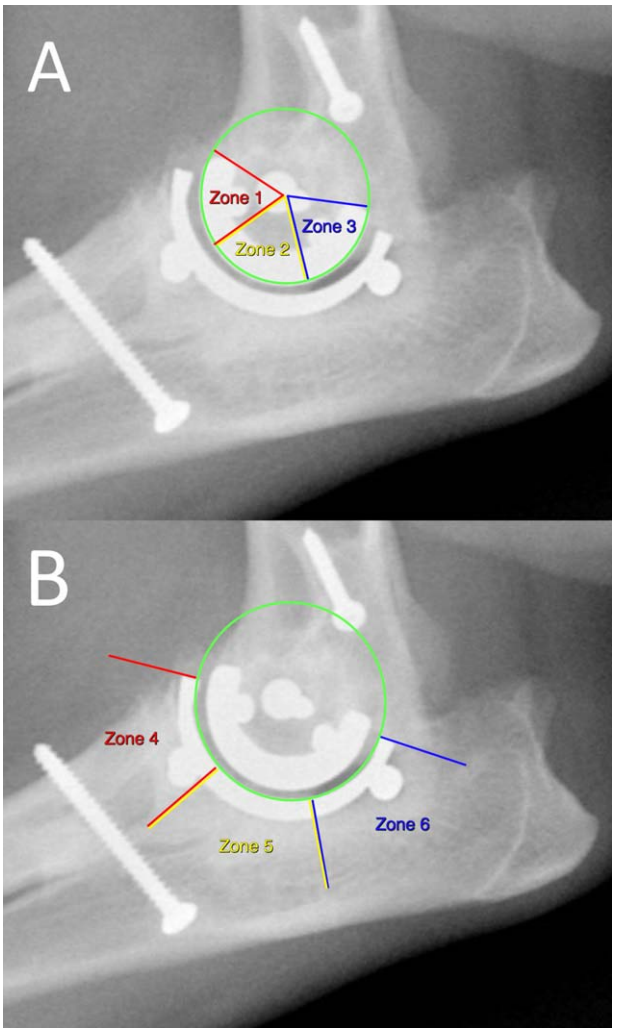

Figure 3 Component zones. (A) Humeral component-bone interface (CBI) zone 1, 2 and 3. (B) Radioulnar CBI zone 4, 5 and 6.

subsequently when requested by other clinicians or the owner. Subjective clinical outcome was classified relative to pre-disease status: 1) full function, where there was restoration or maintenance of the intended activity level and overall performance without medication, 2) acceptable function, when restoration or maintenance of the intended activity level and overall performance was limited in level or duration or required medication, and 3) unacceptable function, when there was severe lameness and pain during manipulation of the elbow.[29]

Statistical Analysis

Data were summarized as mean SD or median (range) as appropriate. Data were assessed for normality with the Shapiro–Wilk test. Pre and postoperative mobility, pain severity and pain interference scores were compared using nonparametric Wilcoxon matched pair tests. The immediate postoperative and final CBI for each of the 6 zones were compared using the Wilcoxon matched pairs test. The change in CBI grades between immediate postoperative radiographs and final radiographs was compared for elbows with and without a radioulnar synostosis screw using a Mann–Whitney test for unpaired data. Intraclass correlation coefficient (ICC) for RUCA, HUA, cartridge angulation, and ulnar component recession measurements were calculated for inter- and intraobserver agreement. The association of component alignment (valgus, neutral, and varus) and association of translation on outcome (poor, satisfactory, or excellent) were both assessed using the chi-square test. The difference in surgery duration and anesthesia duration for infected and noninfected elbows was compared using a t test for unpaired normally distributed data. Where available, the preoperative and 6 week postoperative flexion and extension angles were compared using a paired t test. A $P < .05$ was considered significant for all tests.

RESULTS

Surgeon questionnaires were completed for 33 elbows in 32 dogs, at a mean postoperative time of 36 months (range 12–83). Preoperative clinical signs reported by the owners included (but were not limited to) intermittent or permanent lameness, reluctance to walk, pain in the elbow, and reduced range of motion of the elbow. In all dogs, conservative

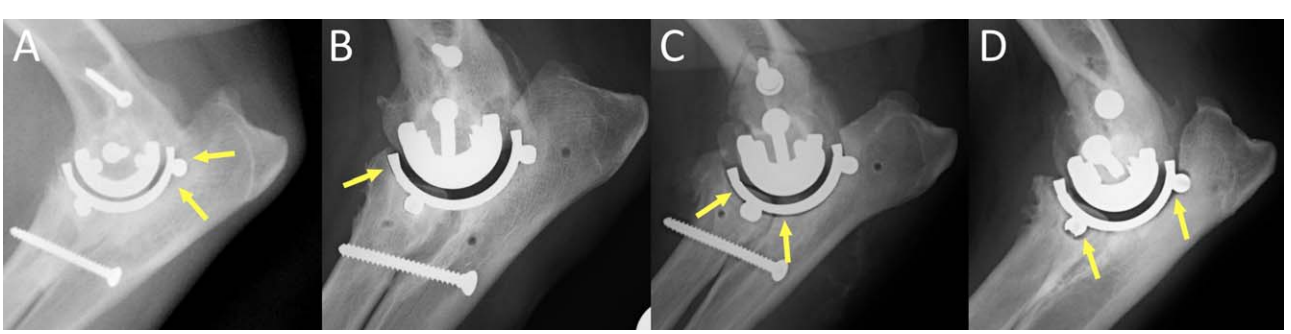

Figure 4 Examples of lucency grading of the radioulnar component. (A) Grade 1: No gap between component and bone in zone 4 and 5 but focal lucency around the caudal ulnar post in zone 6. (B) Grade 2: Gap <1 mm in zone 4. (C) Grade 3: Gap 1-2 mm in zone 4 and 5. (D) Grade 4: Gap in zone 4, 5, and 6, most pronounced around the radial and ulnar posts.

Table 1 Perioperative complications (intraoperative)

Elbow	Complication	Treatment
2	Difficulty inserting cartridge	Re-milling required
10	Malalignment of radioulnar component	Repositioning with post adjustment
12	Epicondylar osteotomy deeper than anticipated	SOP plate added
13	Difficulty placing cartridge; small isthmus	Re-milling required; ulnar DCP plate added
22	Small isthmus	Ulnar DCP plate added
26	Medial collateral ligament damage	Re-enforcement with prosthetic and bone anchors

SOP, string of pearls plate; DCP, dynamic compression plate.

management with weight control, exercise moderation, and anti-inflammatory medication had failed to alleviate clinical signs to a level deemed acceptable to the owner. Eleven dogs had prior arthroscopy of the elbow. The primary cause of end-stage elbow disease was medial coronoid process disease (n=8 elbows), incomplete ossification of the humeral condyle (1), ununited anconeal process (1) and trauma (1) and unknown (22). Dogs ranged in age from 12 to 32 months (median 86), and body weight from 18 to 45 kg (median 33) with a mean (SD) body condition score of 3.3/5 (0.6). There were 21 male (6 entire, 15 neutered) and 11 female (11 neutered) dogs. The most frequent breed was Labrador Retriever (n=18). The onset of lameness before arthroplasty ranged from 5 to 106 months (median 24) and the preoperative lameness score ranged from 4 to 8 out of 10 (median 6). Preoperative goniometric measurements for 15/33 elbows showed a mean (SD) flexion of 61° (18.7°) and mean (SD) extension of 162° (15.4°).

Arthroplasty

Eighteen dogs underwent TATE arthroplasty of the left elbow (4 first generation, 14 second generation) and 15 dogs on the right elbow (3 first generation, 12 second generation). Arthroplasty was performed as described.[30] The medial epicondylar osteotomy was stabilized with cortical screws, with (n=23 elbows) or without (n=10) washers. One screw (n=2 elbows), 2 screws (26), and 3 screws (5) were used without washers. A single cortical screw was used across the condyle with placement of a dynamic compression plate (n=1 dog) or string of pearls plate (SOP, Orthomed, Yorkshire, UK) (3 dogs) along the medial epicondylar ridge.

In 22 elbows, radioulnar synostosis was performed with the placement of a single (n=21 elbows) or 2 radio-ulnar cortical screw (n=1). There was no synostosis implant in 11 elbows. The mean (SD) surgery duration was 248 (61) minutes and general anesthesia duration was 347 (85) minutes. Mean (SD) duration of hospitalization was 5 (3) days. The mean (SD) lameness score at discharge was 6.9 (1.4). Immediate postoperative goniometric measurements recorded in 15/33 elbows showed a mean (SD) flexion of 66° (21.2°) and extension of 163° (13.3°), which were not significantly different from preoperative measurements ($P > .05$). All dogs received intraoperative antibiotics, and received postoperative antibiotics for a mean of 7 (2) days. Owners of 24/33 dogs complied with exercise restriction for a mean (SD) of 6.7 (0.9) weeks. This information was unavailable for 9/33 dogs.

Radiographs

All dogs had an IEWG score of 3, equivalent to severe arthrosis. Medial epicondylar osteotomies healed uneventfully in 31/33 elbows (94%). Component position on mediolateral projections had a mean (SD) RUCA of 117.6° (9.3°), HUA 56.6° (8.1°), ulnar isthmus 11.6 (2.9) mm, ulnar isthmus:cartridge width ratio of 0.9 (0.2) and epicondylar apex height of 27.9 (6.3) mm.

Component position on craniocaudal projections had a mean (SD) RUCA of +4.7° (6.3°). Cartridges were placed in varus malalignment for 56% elbows, valgus malalignment in 6%, and neutral alignment in 37%, relative to the ulnar long axis. Mean (SD) ulnar component recession was +0.1 (2.9) mm with 25% of cartridges being medially translated relative to the ulnar long axis, 44% closely inserted relative to the ulnar long axis, and 31% laterally translated relative to the ulnar long axis. Mean (SD) epicondylar osteotomy height was 33.2 (9.4) mm, EOD was 20.3 (3.9) mm, and humeral metaphyseal width at the level of the osteotomy was 20.3 (3.9) mm. Mean (SD) EOW:HMW was 0.2 (0.1). The ICC were for RUCA (intra-observer 0.96, inter-observer 0.910), HUA (intra-observer 0.96, inter-observer 0.9), cartridge angulation (intra-observer 0.99, inter-observer 0.94), and ulnar component recession (intra-observer 0.98, inter-observer 0.87). Radiographic measurements demonstrated almost perfect agreement for all measurements (ICC>.8).[31]

The CBI grade significantly decreased from immediate postoperative to final radiographs in zone 3 ($P = .017$) but not for any other zone. There was no significant difference in CBI grades for any zone on final radiographs for those with or without presence of a synostosis screw.

Complications

Perioperative complications were reported in 20/33 (60%) elbows, short-term in 5/33 (15%) and mid-term in 5/33 (15%) elbows (Tables [1–3]). All intraoperative, minor, major, and catastrophic complications occurred with second generation implants.

Follow-up and Outcome

Surgeon assessment at 5–8 weeks postoperative was available for 32/33 elbows since one dog was euthanatized at 5 weeks postoperative because of gastric dilatation volvulus. At the time of arthroplasty and owner questionnaire completion, 12/33 dogs had been euthanatized including 11 for reasons unrelated to arthroplasty. The lameness score at 5–8 weeks postoperative ranged from 1 to 10 (median 5). Goniometry was recorded in 14/33 elbows with a mean flexion of 78° (16.1°) and extension of 165° (9.8°). Flexion was significantly reduced from preoperative ($P = .043$) but there was no difference in extension ($P = .39$).

Table 2 Perioperative complications (0–3 months)

Elbow	Complications	Severity	Treatment	Clinical outcome
1	Radioulnar screw breakage	Minor	None	Excellent
2	Radial nervie neurapraxia and exposure of olecranon implants	Major	Implant removal	Poor
4	Loss of reduction of epicondylar osteotomy	Minor	None	Satisfactory
8	Infection	Major	Antibiotics (ongoing)	Poor
9	Olecranon fracture; ulnar nerve entrapment and infection	Catastrophic	Amputation	Poor
17	Missing radioulnar screw at time of arthroplasty	Major	Placement of radioulnar screw	Excellent
20	Infection	Major	Antibiotic and anti-inflammatory medication (6 weeks)	Satisfactory; required ongoing anti-inflammatory medication
23	Fracture medial epicondyle	Major	Revision surgery with 3.5 and 2.7 mm SOP plates applied	Satisfactory; required ongoing anti-inflammatory medication
24	Infection	Major	Antibiotics (8 weeks)	Satisfactory
25	Infection	Major	Antibiotics	Satisfactory
27	Olecranon fracture	Major	2.7 mm T plate and cortical screw	Satisfactory
28	Infection	Major	Antibiotics	Poor
30	Malposition of radioulnar screw	Major	Radioulnar screw re-directed and ulna DCP plate applied	Excellent
33	Infection	Major	Antibiotics (4 weeks)	Excellent

SOP, string of pearls plate.

The time from arthroplasty to final assessment ranged from 4 to 100 months (median 17) with 24% of dogs deemed to have full, 52% acceptable, and 24% unacceptable outcomes on surgeon assessment (Table 4). There was no significant association between outcome and component alignment ($P = .08$) or translation ($P = .06$).

Owner Assessment

Owner questionnaires were completed for 19/33 elbows, at a time ranging from 12 to 50 months (median 33) postoperative. Owners reported the duration of lameness before arthroplasty ranged from 0 to 6 months (n=1 dog), 6–12 months (6), 12–24 months (4), and >36 months (7). The owner of one dog could not report the duration.

There were 32/33 dogs receiving anti-inflammatory medication before arthroplasty and 11/19 dogs at the time of owner questionnaire completion. Two dogs were receiving antibiotics at the time of owner questionnaire.

Owner questionnaires revealed 14/19 would pursue arthroplasty for their dog again, 3/19 said they would not and 2/19 were unsure (Table 4). Owner assessed mobility, pain severity and pain interference aggregate scores were calculated for each dog (Table 5). Comparisons between

Table 3 Short and mid-term complications

Elbow	Complications	Severity	Treatment	Clinical outcome
Short-term (3–6 months)				
21	Infection	Major	Antibiotics	Satisfactory
26	Radioulnar screw breakage	Major	SOP plate and radioulnar screw removed	Satisfactory
27	Re-fracture of olecranon	Major	1.6 mm tension band wire	Satisfactory
28	Infection	Major	Antibiotics (ongoing)	Poor
29	Infection	Major	Antibiotics	Excellent
Midterm (6–12 months)				
2	Infection and implant loosening	Catastrophic	Antibiotic and anti-inflammatory medication	Poor
15	Loosening of the radioulnar screw	Major	Radioulnar screw removed	Satisfactory
25	Implant loosening	Catastrophic	Arthrodesis	Poor
27	Infection, implant loosening	Catastrophic	Amputation	Poor
28	Infection, arthrodesis, radial nerve neurapraxia	Catastrophic	Euthanatized	Poor

SOP, string of pearls plate.

Table 4 Surgeon and owner assessment and satisfaction

Weeks to assessment of optimum function (number dogs)	8	8–24	24–36	36–48	48–72	Never	Unknown
Surgeon	1	10	7	6	1	5	3
Owner	–	5	2	4	3	4	1

Satisfaction with surgical procedure (number dogs)	Extremely satisfied	Very satisfied	Satisfied	Dissatisfied	Somewhat disappointed	Indifferent	Unknown
Surgeon	6	8	11	8	–	–	–
Owner	–	12	–	–	5	1	1

preoperative and final status showed significant reductions in pain severity ($P = .01$) and pain interference ($P < .01$) but no changes in mobility scores ($P = .19$).

DISCUSSION

This study defined criteria for radiographic assessment of components of first and second generation TATE arthroplasty, and established metrics for surgeon and owner assessment of outcome after this surgery.

Reports after TATE arthroplasty have had limited case numbers,[14,15] without quantitative assessment of component position, bone interfaces, or their association with clinical outcome. Component implantation with accurate reconstruction of the anatomic axis is critical for functional outcome in human elbow arthroplasty.[32,33] An ex vivo kinematic assessment of the TATE arthroplasty in dogs showed 2/10 dogs had components that were malpositioned resulting in translation of the central rotational axis of the elbow.[30] The present study had imperfect alignment of the components in at least one plane in 97% of elbows, defined as greater than 5° valgus or varus, or greater than 2 mm medial or lateral translation. The majority of malaligned components were in both varus and lateral translation. Access to the humeral condyle for optimum alignment of the condylar clamp with the humeral long axis can be challenging because of severe fibrosis and presence of osteophytes that can force the condylar clamp into varus malalignment, causing inaccurate direction of drill, mill, and cartridge placement (Fig 5).[30] The depth of the mill for cartilage placement is not currently based on any radiographic measurement of humeroulnar width but is referenced from the medial caudal ulnar trochlea and medial coronoid process at the time of arthroplasty. It is suggested that the medial aspect of the trial component, and subsequently the radioulnar component, should be flush with the medial caudal ulnar trochlea. However, this does not take into consideration the variable width of the ulna between dogs. In a dog with an ulnar width less than the width of the trial and radioulnar component, this will predispose to over-milling of the elbow and malalignment of components in lateral translation relative to the long axis of the ulna. If osteophytes on the caudomedial aspect of the ulnar trochlear are misinterpreted as the ulna proper, this can predispose to under-milling of the elbow and malalignment of components in medial translation. Implant malalignment and cartridges translated relative to the ulnar long axis could predispose to uneven wear of components and component loosening, as reported after elbow arthroplasty in people.[33,34] The experience in the present study found the current TATE instrumentation affords the surgeon influence over final alignment of components, and implant position did not appear to affect outcome. Thus, tolerance to malalignment of the TATE components is apparent, similar to findings with canine hip replacement components.[35]

Table 5 Preoperative and final aggregate scores for owner assessment of mobility, pain severity, and pain interference

	LOAD Mobility		CBPI Pain severity		CBPI Pain interference	
	Median	Mean	Median	Mean	Median	Mean
Preoperative	21.5	20.3	5	4.7	5	5.1
Final	18.5	19.6	1	1.9	2	2.5

LOAD, Liverpool osteoarthritis in dogs; CBPI, canine brief pain inventory.

Analysis of bone-implant interface within zones was used to assess radiographic signs of interface stability or bone resorption. Cases where infection was identified were not assessed since infection may confound any changes noted. Radiographic assessment within zones around arthroplasty components is employed for assessment in human arthroplasty.[36,37] Results showed a significant decrease in CBI grade in zone 3, consistent with a reduced interface gap at this site (Fig 4A). This zone corresponded to the caudal third of the humeral-component, thus the change in grade is consistent with stability and progressive osteointergration at this site, concordant with pilot histologic findings of a retrieved TATE cartridge.[14]

The first and second generation cartridges have a combined radioulnar component so synostosis of the proximal radius and ulna is recommended to restrict supination and

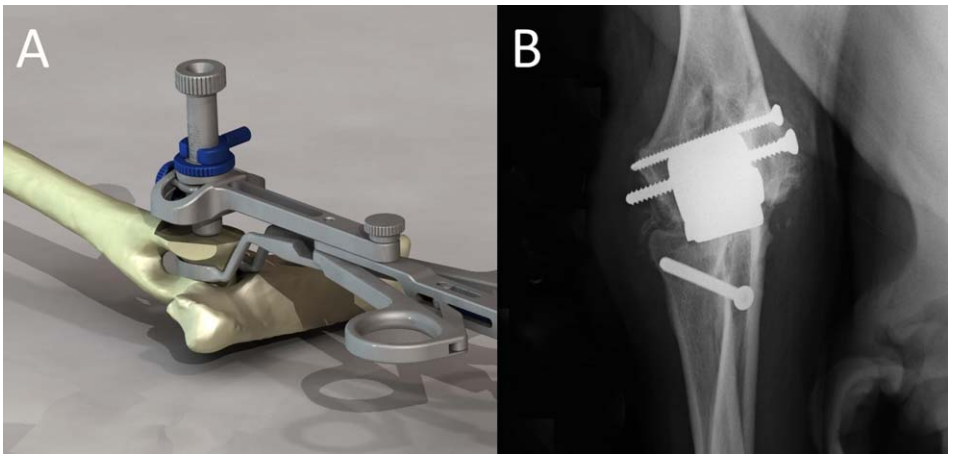

Figure 5 Affect of condylar clamp placement of component alignment (Figure provided courtesy of BioMedtrix). (A) Placement of condylar clamp on humeral trochlea. Note the trochlear clamp is resting on the medial aspect of the ulnar. Inadequate lateral subluxation of the ulna because of fibrosis or osteophyte may cause malalignment of the condylar clamp on the humerus when the clamp is forced into varus malalignment by the medial aspect of the ulna. This causes varus placement of the center of the rotation pin placed through the humeral condyle with subsequent varus malalignment of the components. Varus malalignment occurred in 74% of cartridges placed. (B) Caudocranial radiograph of dog 4. Note the cartridge is placed in varus malalignment.

pronation that may induce shear forces at the radioulnar CBI.[38] However, no difference was noted in the zones of the humeral and radioulnar component of dogs with or without synostosis implants, suggesting a synostosis screw may be unnecessary for stability of humeral and radioulnar CBI. Extended radiographic follow-up and histologic assessment of retrieved components from dogs with and without synostosis screws would be required to further characterize any differences in osteointegration between these cohorts.

Ground reaction forces were not measured in this study. Instead, scaled questionnaires were used to record owner perception of their dog's pain and function. Significant reduction in scores for pain severity and pain interference coincided with a lower number of dogs receiving (requiring) anti-inflammatory medication at the final assessment. Mobility scores did not significantly change. Mean elbow flexion was less than normal preoperatively[26] and was significantly reduced from this level at 6–8 weeks postoperative, possibly contributing a mechanical component to persistent lameness. This may explain why pain severity was significantly reduced but mobility did not change.

Intraoperative complications occurred in 6 elbows (24%), of which 3 were iatrogenic. Surgeons performing canine hip arthroplasty have an initial learning curve of 44 surgeries before achieving consistent results.[39] The maximum number of procedures performed by one surgeon in the present study was 15, which may represent less than required for attaining optimum results for TATE arthroplasty. Thus, the occurrence of complications in this study may be higher than expected with more experience. Postoperative complications have been reported with other canine elbow arthroplasty systems.[11,12] In this study, the occurrence of postoperative complications was high, with infection the most frequent. Of 11 dogs suspected to have postoperative infection, 5 had resolution with antibiotics administered for >6 weeks. Bacterial culture from 4 dogs showed growth of *Staphylococcus spp*. in 3 and no growth in 1. Similarly to previous studies,[40] prolonged general anesthesia and surgery duration may contribute to risk for infection.

Two dogs had fracture of the olecranon, stabilized with a bone plate applied to the caudal aspect of the ulna. In both dogs, the ulnar isthmus:cartridge width ratio was greater than the mean of elbows analyzed, which may have contributed to fracture. The frequency of olecranon fracture in this study (6%) is similar to that described for elbow arthroplasty in people.[41]

Healing of the medial epicondylar osteotomy was uneventful in 31 elbows. One elbow developed a delayed union. This dog was overweight and had the highest medial EOD (9.7 mm) and EOD:HMW (0.44) in the study. One elbow showed loss of reduction of the epicondylar osteotomy at 6 weeks postoperative. Immediate postoperative radiographs of this elbow showed the lowest EOD:HMW in the study. Other observations showed no difference in osteotomy healing for dogs with a transcondylar screw using a single epicondylar screw vs. a transcondylar screw combined with an epicondylar plate and screws. Thus, epicondylar fixation with a plate and screws may be unnecessary. Similarly, osteotomy healing with screw fixation with and without washers was not different, suggesting washers are unnecessary.

Information in this study was accessed retrospectively from clinical records and was incomplete in a minority of dogs; however, the reported complications could be underestimated. The lameness assessments were subjective and dog owners were asked to recall preoperative information. The validity of recalled data using LOAD and CPBI is not known, but LOAD has been used retrospectively in the assessment of function after canine total hip replacement.[24]

Owners may underestimate elbow lameness as a function of increasing time following elbow surgery when compared with quantitative measures of gait.[42] This could bias the results of the study positively. No information was obtained on the status of the contralateral elbow, which could influence the overall function, mobility, and pain scores. Involvement of multiple centers in the study allowed accrual of more cases but introduces variability in surgical technique, facilities, and postoperative management, especially when assessed retrospectively. The analysis of CBI could only be measured on a mediolateral radiograph where the humeral and radioulnar components did not obscure the interface. However, a degree of obliquity in the components was present in some radiographs, which made assessment difficult. This, coupled with variation in position and exposure among radiographs, introduces imprecision in scoring.

This study showed considerable variability in placement of TATE elbow arthroplasty components and occurrence of complications; however, component malalignment did not appear to influence clinical outcome. Surgeons and owners made favorable assessments of outcome in a majority of dogs, noting significant reduction in pain and improvement in quality of life after this surgical procedure.

ACKNOWLEDGMENTS

The authors acknowledge Novartis for access to the LOAD questionnaire.

DISCLOSURE

The authors declare no conflicts of interest related to this report.

REFERENCES

1. Morgan J, Wind A, Davidson AP (eds): Elbow dysplasia, in *Hereditary bone and joint diseases in the dog* (1st ed 1). Hannover, Schultersche, 2000, pp 41–68
2. Ness MG: Treatment of fragmented coronoid process in young dogs by proximal ulnar osteotomy. *J Small Anim Pract* 1998; 39:15–18
3. Fitzpatrick N, Yeadon R, Smith T, et al: Techniques of application and initial clinical experience with sliding humeral osteotomy for treatment of medial compartment disease of the canine elbow. *Vet Surg* 2009;38:261–278
4. Fitzpatrick N: Biceps ulnar release procedure for treatment of medial coronoid disease in 49 elbows. Proc 36th Annual Conference, Veterinary Orthopaedic Society, Steamboat Springs, CO, 2009, p 44
5. Fitzpatrick N: Subtotal coronoid ostectomy: indications and outcome. Proc American College of Veterinary Surgeons Symposium, Chicago, IL, 2011, p 113
6. Stark A, Bottcher P, Pfeil I: Comparative radiologic examination of the canine elbow with and without elbow dysplasia under standardized load. *Tierarztl Prax Ausq K Kleintiere Heimtiere* 2014;42:141–150
7. Franklin SP, Cook JL: Prospective trial of autologous conditioned plasma versus hyaluronan plus corticosteroid for elbow osteoarthritis in dogs. *Can Vet J* 2013;54:881–884
8. Kunst CM, Pease AP, Nelson NC et al: Computed tomographic identification of dysplasia and progression of osteoarthritis in dog elbows previously assigned OFA grades 0 and 1. *Vet Radiol Ultrasound* 2014;55:511–520
9. Lewis RH: Development of elbow arthroplasty (Canine) Clinical trials. Proc 6th Annual ACVS Symposium. San Francisco, CA, 1996, p 110
10. Conzemius MG, Aper RL, Hill CM: Evaluation of a canine total elbow arthroplasty system. A preliminary study in normal dogs. *Vet Surg* 2001;30:11–20
11. Conzemius MG, Aper RL, Corti LB: Short-term outcome after total elbow arthropasty in dogs with severe, naturally occurring osteoarthritis. *Vet Surg* 2003;32:545–552
12. Innes JF: Complications with Iowa State TER and how this has informed development of the Sirius Total Elbow Replacement. Proc British Veterinary Association Autumn Meeting, Bristol, UK, 2011, p 18-20
13. Smith ZF, Wendelburg KL, Tepic S, et al: In vitro biomechanical comparison of load to failure testing of a canine unconstrained medial compartment elbow arthroplasty system and normal canine thoracic limbs. *Vet Comp Orthop Traumatol* 2013;26:356–365
14. Déjardin LM, Guillou RP: Total elbow replacement in dogs. Proc 16th European Society of Veterinary Orthopaedics and Traumatology Congress, Bologna, Italy, 2012, p 147–149
15. Acker R, Van Der Meulen G, Sidebotham C: Preliminary evaluation of the TATE Elbow total arthroplasty system in client owned dogs. Proc 14th European Society of Veterinary Orthopaedics and Traumatology Congress, Munich, Germany, 2008, p 13
16. Marshall DA, Pykerman K, Werle J, et al: Hip resurfacing versus total hip arthroplasty: a systematic review comparing standardized outcomes. *Clin Orthop Relat Res* 2014;472:2217–2230
17. Burton NJ, Dobney JA, Owen MR, et al: Joint angle, moment and power compensations in dogs with fragmented medial coronoid process. *Vet Comp Orthop Traumatol* 2008;21: 110–118
18. Brown DC, Boston RC, Farrar JT: Use of an activity monitor to detect response to treatment in dogs with osteoarthritis. *J Am Vet Med Assoc* 2010;237:66–70
19. Brown DC, Boston RC, Coyne JC, et al: Ability of the Canine Brief Pain Inventory to detect response to treatment in dogs with osteoarthritis. *J Am Vet Med Assoc* 2008;233:1278–1283
20. Brown DC, Bell M, Rhodes L: Power of treatment success definitions when the Canine Brief Pain Inventory is used to evaluate carprofen treatment for the control of pain and inflammation in dogs with osteoarthritis. *Am J Vet Res* 2013;74: 1467–1473
21. Hielm-Björkman AK, Rita H, Tulamo RM: Psychometric testing of the Helsinki chronic pain index by completion of a questionnaire in Finnish by owners of dogs with chronic signs of pain caused by osteoarthritis. *Am J Vet Res* 2009;70: 727–734

22. Walton MB, Cowderoy E, Lascelles D, et al: Evaluation of construct and criterion validity for the 'Liverpool Osteoarthritis in Dogs' (LOAD) clinical metrology instrument and comparison to two other instruments. *PLoS One* 2013;8:e58125
23. Hercock CA, Pinchbeck G, Giejda A, et al: Validation of a client-based clinical metrology instrument for the evaluation of canine elbow osteoarthritis. *J Small Anim Pract* 2009;50:266–271
24. Forster KE, Wills A, Torrington AM, et al: Complications and owner assessment of canine total hip replacement: a multicenter internet based survey. *Vet Surg* 2012;41:545–550
25. Likert R: A technique for the measurement of attitudes. *Arch Psychol* 1932;140:1–55
26. Jaegger G, Marcellin-Little DJ, Levine D: Reliability of goniometry in Labrador Retrievers. *Am J Vet Res* 2002;63:979–986
27. International elbow working group protocol. *Vet Radiol Ultrasound* 1995;36:172–173
28. Wood MC, Fox DB, Tomlinson JL: Determinations of the mechanical axis and joint orientation lines in the canine humerus: a radiographic cadaveric study. *Vet Surg* 2014;43:414–417
29. Cook JL, Evans R, Conzemius MG, et al: Proposed definitions and criteria for reporting time frame, outcome, and complications for clinical orthopaedic studies in veterinary medicine. *Vet Surg* 2010;39:905–908
30. Burton NJ, Ellis JR, Burton KJ, et al: An ex vivo investigation of the effect of the TATE canine elbow arthroplasty system on Kinematics of the elbow. *J Small Anim Pract* 2013;54:240–247
31. Landis JR, Koch GG: The measurement of observer agreement for categorical data. *Biometrics* 1977;33:159–174
32. Doheny EP, Lowery MM, O'Malley MJ, et al: The effect of elbow joint centre displacement on force generation and neural excitation. *Med Biol Eng Comput* 2009;47:589–598
33. Van der Lugt JC, Rozing PM: Systematic review of primary total elbow prosthesis used to the rheumatoid elbow. *Clin Rheumatol* 2004,23:291–298
34. Trall IA, Nuttall D, Stanley JK: Survivorship and radiological analysis of the standard Douter-Strathclyde total elbow arthroplasty. *J Bone Joint Surg* 1999;81:80–84
35. Edwards MR, Egger EL, Schwartz PD: Aseptic loosening of the femoral implant after cemented total hip arthroplasty in dogs: 11 cases in 10 dogs (1991-1995). *J Am Vet Med Assoc* 1997; 211:580–586
36. DeLee JG, Charnley J: Radiologic demarcation of cemented sockets in total hip replacement. *Clin Orthop Relat Res* 1976; 121:20–32
37. Gruen TA, McNeice GM, Amstutz HC: "Modes of failure" of cemented stem-type femoral components: a radiographic analysis of loosening. *Clin Orthop Relat Res* 1979;141: 17–27
38. Dejardin L, Guillou R: Radioulnar Synostosis, in: Proc BioMedtrix TATE Elbow Workshop 25th April, Glasgow, UK, 2009, p 13
39. Hayes GM, Ramirez J, Langley Hobbs SJ: Use of the cumulative summation technique to quantitatively assess a surgical learning curve: canine total hip replacement. *Vet Surg* 2011;40:1–5
40. Brown DC, Conzemius MG, Shofer F, et al: Epidemiologic evaluation of postoperative wound infections in dogs and cats. *J Am Vet Med Assoc* 1997;210:1302–1306
41. Zafiropoulos G, Amis AA: Fixation strength of the ulnar component of total elbow replacement. *J Shoulder Elbow Surg* 1996;5:102
42. Burton NJ, Owen MR, Colborn GR, et al: Can owners and clinicians assess outcome in dogs with fragmented medial coronoid process? *Vet Comp Orthop Traumatol.* 2009;22: 183–189

SUPPORTING INFORMATION

Additional Supporting Information may be found in the online version of this article at the publisher's web-site:

Supplement 1. TATE Elbow arthroplasty questionnaire for surgeons.

Supplement 2. Owner assessment questionnaire.